

Clinical correlates with anti-MuSK antibodies in generalized seronegative myasthenia gravis

Amelia Evoli,¹ Pietro A. Tonali,¹ Luca Padua,¹ Mauro Lo Monaco,¹ Flavia Scuderi,² Anna P. Batocchi,¹ Mariapaola Marino² and Emanuela Bartoccioni²

Departments of ¹Neuroscience and ²General Pathology, Catholic University, Roma, Italy

Correspondence to: Amelia Evoli MD, Neuroscience Department, Catholic University, Largo F. Vito, 1, 00168 Roma, Italy
E-mail: a.evoli@rm.unicatt.it

Summary

The term seronegative myasthenia gravis (SNMG) refers to the generalized disease without detectable anti-acetylcholine receptor (anti-AChR) antibodies. In these patients, IgG antibodies against the muscle-specific kinase (MuSK) have been described, which reduced agrin-induced AChR clustering *in vitro*. We have assayed anti-MuSK antibodies in 78 patients with SNMG, who have been followed for many years in our Institution. Here we describe the clinical phenotype of the 37 patients whose results were positive on this assay. MG with anti-MuSK antibodies was characterized by a striking prevalence of female patients (eight men and 29 women). Age of onset ranged from 6 to 68 years, with 56.8% of patients presenting under 40 years of age. All these patients shared a similar pattern of muscle weakness, with prevalent involvement of cranial and bulbar muscles and a high frequency of respiratory crises; the involvement of limb muscles was comparatively less severe and inconsistent. Single-fibre-EMG confirmed the most sensitive examination in the EMG diagnosis of MuSK-positive disease, while, owing to weakness topography, repetitive nerve stimulation in limb muscles was diagnostic in 56.8% of cases. The

effect of edrophonium (or neostigmine) injection was equivocal or negative in 11 of 37 patients (29.7%), and the response to oral pyridostigmine was even more unsatisfactory, ranging from mild benefit to overt intolerance. In thymectomized patients, thymus was normal for age or atrophied, and no benefit from surgery was noticed. Thirty-five of 37 patients were given immunosuppressive therapy and 22 received plasma-exchange. The course of the disease was often characterized by periodic exacerbation phases requiring hospitalization and even assisted ventilation; plasma-exchange produced marked improvement in these cases. At the end of the observation period, most patients, although improved, were still symptomatic, having developed permanent facial and pharyngeal weakness together with some atrophy of facial muscles. MuSK-negative disease was comparatively more heterogeneous. Most patients were affected with mild to moderate symptoms and responded well to pharmacological treatment; however, a few subjects in this group had severe refractory disease, poorly responsive to both acetylcholinesterase inhibitors and immunosuppressants.

Keywords: myasthenia gravis; seronegative myasthenia gravis; MuSK; SF-EMG; plasma exchange

Abbreviations: AChR = acetylcholine receptor; AChEI = acetylcholinesterase inhibitor; CMAP = compound muscle action potential; IVIG = intravenous immunoglobulin; MG = myasthenia gravis; MGFA = Myasthenia Gravis Foundation of America; MHC = major histocompatibility complex; MuSK = muscle-specific kinase; P-E = plasma-exchange; RNS = repetitive nerve stimulation; SF-EMG = single-fibre EMG; SNMG = seronegative MG; SPMG = seropositive MG

Introduction

About 10% of patients with generalized myasthenia gravis (MG) do not have detectable serum antibodies to acetylcholine receptor (AChR) on conventional radioimmunoassay. In these cases, the disease is commonly referred to as seronegative MG (SNMG).

From the initial observations, SNMG has been recognized as an antibody-mediated disease (Mossman *et al.*, 1986; Vincent *et al.*, 1993); however, the target antigen has long remained elusive. The report by Hoch *et al.* (2001) that a proportion of these patients have serum IgG antibodies

against the muscle-specific kinase (MuSK) has shed new light on the pathogenesis of the disease. Anti-MuSK antibodies very probably impair neuromuscular transmission, as MuSK plays a critical role in postsynaptic differentiation and AChR clustering (DeChiara *et al.*, 1996). In addition, in some SNMG patients, a non-IgG plasma factor has been described that inhibits AChR function through increased AChR phosphorylation; interestingly, this activity has been found in both anti-MuSK positive and -negative sera (Plested *et al.*, 2002).

On clinical grounds, it was soon recognized that the absence of anti-AChR antibodies does not necessarily mean mild disease; in particular, the frequency of severe symptoms and the use of immunosuppressive therapy were reported to be similar in patients with anti-AChR-positive (seropositive MG; SPMG) and SNMG (Birmanns *et al.*, 1991). In 1996, we described a subgroup of SNMG patients with a distinctive clinical picture, characterized by a prevalent involvement of cranial and bulbar muscles, high incidence of respiratory crises and a response to immunosuppressive treatment less satisfactory than that observed in SPMG (Evoli *et al.*, 1996). We subsequently reported that these clinical features were significantly associated with the presence of anti-MuSK antibodies (Scuderi *et al.*, 2002); this finding has recently been confirmed by other authors (Vincent *et al.*, 2003).

Here we describe the clinical features associated with the presence of anti-MuSK antibodies in a large series of SNMG patients, who have been followed for many years in our Institution.

Patients and methods

SNMG diagnosis

The study included 78 patients diagnosed with SNMG. All these subjects had generalized MG, as defined by the Myasthenia Gravis Foundation of America (MGFA) classification (Jaretzki *et al.*, 2000) (i.e. a disease affecting other than ocular muscles, although ocular muscle weakness could be associated) and had resulted repeatedly negative on anti-AChR antibody assay.

The diagnosis of SNMG was based on the association of fatigable muscle weakness together with EMG evidence of neuromuscular transmission defect as a decrement of >11% in the amplitude of the compound muscle action potential (CMAP) on low-rate repetitive nerve stimulation (RNS) or increased jitter on single-fibre EMG (SF-EMG). A positive response to the injection of acetylcholinesterase inhibitors (AChEIs) (neostigmine i.m. or edrophonium i.v.) was considered as an additional element in favour of the diagnosis. All patients had RNS in distal (abductor digiti quinti) and proximal (deltoid) muscles as routine protocol; in all cases with negative results, SF-EMG of facial muscles, either orbicularis oculi or frontalis, was performed. CMAP increment on high-rate RNS (or maximum voluntary contraction) and a repetitive response to single nerve stimulus were absent. In order to rule out neurogenic or myopathic

disorders, the following investigations were performed: needle EMG examination, nerve conduction studies and serum creatine kinase evaluation in all patients; serum lactate measurement in most cases; muscle biopsy in 16 of 78 patients.

Anti-AChR antibodies were tested by standard radioimmunoassay (Lindstrom, 1977), with minor modifications (Bartocioni *et al.*, 1980), in serum samples taken before immunosuppressive therapy, when possible. All sera with a negative value (<0.5 nM) were re-assayed with different antigen extracts to confirm the absence of anti-AChR antibodies.

Anti-MuSK antibody testing

Anti-MuSK antibodies were assayed as previously described (Scuderi *et al.*, 2002). Briefly, N-terminal residues of membrane proteins from TE671 cells were biotinylated according to Schuberth *et al.* (1996). The biotinylated cell pellets were lysed with 1 ml of 1% Triton-X100 in 50 mM Tris-HCl, 2 mM EDTA pH 8, 1 mM phenylmethylsulfonyl fluoride (PMSF), 1 mM Na-orthovanadate (lysis buffer). Lysate proteins (1 mg) were precipitated with 5 µl of patients' serum and 10 µl of protein G-Sepharose for 3 h at 4°C, with continuous shaking. The immunoprecipitates were dissolved in 30 µl of lysis buffer/SDS (sodium dodecylsulfate) sample buffer (Tris-HCl pH 6.8, 10% SDS, 36% glycerine, 5% 2-mercaptoethanol, 0.03% bromophenol blue) (6/1, v/v); samples were electrophoresed on an SDS-polyacrylamide gel in a Mini Protean 3 Cell Powerpack 300 System (Bio-Rad). Gels were blotted with transfer buffer (30 mM Tris, 240 mM glycine, 20% methanol) directly on pure nitrocellulose membrane (0.45 µm) (Bio-Rad, Hemel Hempstead, UK) at 330 mA for 1 h in a Mini Trans-Blot Transfer Cell (Bio-Rad). Biotinylated proteins were stained with horseradish peroxidase (HRP)-conjugated avidin (1 : 20 000) and enhanced chemiluminescence detection was performed by exposition on a Kodak XAR-5 X-ray film. To verify the presence of MuSK in the immunoprecipitated proteins, we stripped off and reprobated blots with a rabbit anti-MuSK antiserum (kindly given by M. A. Ruegg, Basel). To detect the immunolabelled proteins, blots were incubated with goat anti-rabbit HRP-conjugated antiserum (Bio-Rad).

Anti-MuSK antibodies were assayed in serum samples from the 78 SNMG patients, 30 SPMG cases and 20 healthy subjects.

MG grading and treatment, thymus histology

All patients had generalized symptoms. Disease severity was graded according to the MGFA classification (Jaretzki *et al.*, 2000). Pharmacological therapy was performed with oral AChEI (pyridostigmine) when effective; it was associated with immunosuppressive drugs in patients with disabling weakness, according to current indications (Keeseey, 1998). Prednisone was usually started at a high daily dosage (0.8–

1 mg/kg), gradually shifting to an alternate-day schedule, followed by progressive reduction to the minimum maintenance dose or withdrawal. Azathioprine was used at a starting dose of 2.5–3 mg/kg/day and was gradually reduced to the maintenance dose of 1 mg/kg/day. Cyclosporin A was used in patients with contraindications or unsatisfactory response to azathioprine at a starting dose of 3–5 mg/kg/day and at maintenance doses of 2–4 mg/kg/day. Plasma-exchange (P-E) and intravenous immunoglobulin (IVIG) were used in association with immunosuppressive drugs as ‘emergency therapy’ in treating patients with severe bulbar symptoms and/or respiratory crises or as periodic treatment in patients not satisfactorily controlled with immunosuppressants.

Follow-up ranged from 0.5 to 25 years (mean 10 years). At the end of the follow-up period (January 2003), response to treatment was evaluated according to the MGFA recommendations (Jaretzki *et al.*, 2000).

Thymus sections were available from 29 patients who had undergone thymectomy. Haematoxylin and eosin-stained sections from 12 MuSK-positive and 17 MuSK-negative subjects were reviewed and thymus histology was re-classified (Verma and Oger, 1992).

Statistical analysis was performed by Student’s *t* test and χ^2 test with Yates correction.

Results

Anti-MuSK antibodies were detected in 37 of 78 SNMG patients (47.4%); they tested negative in the 30 SPMG patients and in the 20 healthy controls.

Epidemiology

In the MuSK-positive group, there was a striking prevalence of female patients (eight men and 29 women, M/F = 0.3), whereas, in the MuSK-negative series, no significant difference in gender was found (20 men and 21 women, M/F = 0.9). Age at disease onset ranged from 6 to 68 years in MuSK-positive and from 11 to 83 years in MuSK-negative patients. Although the mean age of onset was similar (35 and 39 years, respectively), MuSK-positive disease was more frequent in younger subjects, with 56.8% of patients presenting under 40 years of age. These data are shown in Fig. 1.

Two cases of familial MG were found. The father of a MuSK-positive patient had been affected with early-onset AChR-positive generalized MG; no linkage with major histocompatibility complex (MHC) genes was observed in this family (Evoli *et al.*, 1995). In another family, late-onset AChR-positive ocular myasthenia was diagnosed in the father of a MuSK-negative SNMG subject; no genetic study has been performed in these cases.

Clinical features

In MuSK-positive patients, the disease frequently showed an acute or subacute onset. The presenting symptoms, in most

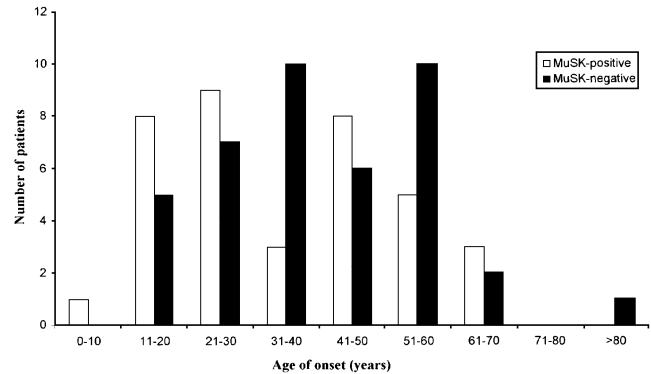


Fig. 1 Age of onset in MuSK-positive and MuSK-negative patients.

cases, were ptosis and diplopia; weakness rapidly progressed to bulbar muscles, which remained the most severely affected throughout the course of the disease. All these patients shared a similar pattern of muscle involvement: dysarthria (nasal speech) and facial weakness were present in all cases, swallowing difficulties caused by weakness of both tongue and pharyngeal muscles, and ocular disturbances occurred in 35 out of 37; respiratory crises were remarkably frequent, but in no case constituted the presenting symptom. Involvement of limb muscles was comparatively less severe and inconsistent: in particular, 21 of 37 patients complained of limb fatigability alone, while a clear-cut weakness was evident in 12 cases. The maximum MG severity was the following: mild disease in six cases (class IIa in two and IIb in four), moderate disease (class IIIb) in 12 and severe disease (grade IVb) in two; 17 patients experienced, during the course of the disease, one or more respiratory crises requiring assisted ventilation (grade V).

In MuSK-negative patients, the clinical picture was more heterogeneous. Most patients were affected by mild disease; limb muscles were more commonly affected and bulbar signs were both less frequent and less severe than in MuSK-positive subjects; respiratory crises occurred in three of 41 patients. The maximum MG severity was the following: mild disease in 25 cases (class IIa in 20 and IIb in five), moderate disease in 12 (class IIIa in five and IIIb in seven), class IV in one and class V in three. Table 1 reports the pattern of muscle involvement, and Table 2 summarizes the maximum MG severity in the two patient groups. The MuSK-positive series was characterized by a significantly increased rate of severe clinical forms, in particular by a higher frequency of respiratory crises.

MG diagnosis

In the MuSK-positive series, a significant CMAP decrement on RNS in limb muscles was evident in 21 of 37 patients (56.8%); SF-EMG of facial muscles showed abnormal jitter in the other 16 cases. The effect of edrophonium or neostigmine injection was positive in 26 cases (70.3 %),

Table 1 Pattern of muscle involvement

Clinical signs	MuSK-positive (n = 37)	P	MuSK-negative (n = 41)
Bulbar weakness	37 (100%)	<0.0001	24 (58.5%)
Ophthalmoparesis	35 (94.6%)	NS	38 (92.7%)
Limb weakness	12 (32.4%)	NS	21 (51.2%)
Limb fatigability	21 (56.8%)	NS	20 (48.8%)
Respiratory crises	17 (46%)	<0.0003	3 (7.3%)

NS = not significant.

Table 2 Maximum disease severity

MG severity*	MuSK-positive (n = 37)	P	MuSK-negative (n = 41)
Class II	6 (16.2%)	<0.0001	25 (61%)
IIa	2		20
IIb	4		5
Class III	12 (32.4%)	NS	12 (29.3%)
IIIa	–		5
IIIb	12		7
Class IV	2 (5.4%)	NS	1 (2.4%)
IVa	–		–
IVb	2		1
Class V	17 (46%)	<0.0003	3 (7.3%)

*According to the MGFA classification; NS = not significant.

equivocal or negative in nine; in two additional patients, it actually worsened symptoms; in 10 patients, AChEI injection caused widespread fasciculations. Muscle biopsy was performed in 13 patients; in nine of these cases, who were studied in our Institution, we found the same abnormalities as in SPMG, consisting of increased fibre diameter variability, single-fibre atrophy and scattered focal necrosis.

Low-rate RNS in limb muscles resulted positive in 32 of 41 MuSK-negative patients (78%); SF-EMG of facial muscles showed increased jitter in the other cases. The response to edrophonium or neostigmine test was clearly positive in 34 of 41 patients (82.9 %) and equivocal or negative in seven; in no case did AChEI injection cause worsening of clinical signs. One patient in this group had motor axonal neuropathy associated with chronic renal failure; muscle biopsy was consistent with this condition. Muscle biopsy was performed in two additional cases, with the same findings as in the MuSK-positive cases.

Clinical course in MuSK-positive patients

All but two of the 37 subjects in this group were given immunosuppressive therapy: 14 were treated with prednisone alone, 16 with prednisone and azathioprine, and five with prednisone and cyclosporin A. Twenty-two patients received P-E, and 11 of these cases with refractory disease required periodic P-E courses; seven patients were given one or more IVIG infusions.

Fifteen patients underwent thymectomy; histological findings were of 'normal for age' or atrophied thymuses; in no

cases were germinal centres found. At the time of surgery, patients' age ranged from 11 to 41 years (mean 25 years); 13 of 15 patients were under immunosuppression, generally with prednisone. Most of these subjects remained dependent on immunosuppressive treatment after surgery.

Response to pyridostigmine ranged from mild benefit to ineffectiveness; thus most patients omitted AChEI treatment early in the course of the disease, also on account of painful cramps and other cholinergic side effects. Five subjects showed overt intolerance to pyridostigmine, as described in case report no.1.

Thirty of 35 patients improved on immunosuppressive therapy; however, nearly 30% of MuSK-positive subjects (11 out of 37), while on high-dose immunosuppression, suffered from periodic disease deteriorations, characterized by severe generalized weakness (including ocular and limb muscles), feeding difficulties and, in some cases, respiratory crises. All these patients markedly improved on P-E, as described in case report no. 2.

The course of the disease was unstable in the first years from onset, then it became more steady. At the end of the observation period, therapeutic results were the following: complete stable remission in three patients, pharmacological remission in four, minimal manifestations in four, 21 subjects had improved, but still showed clear symptoms, three remained unchanged and two had died of respiratory crises. All but one patient who achieved good therapeutic results had received immunosuppressive therapy. On the other hand, thymectomy was not associated with a better outcome. The status at last examination in relation to treatment is shown in

Table 3 Status in relation to treatment

Status at last examination	Musk-positive patients (n = 37)				Musk-negative patients (n = 41)			
	Immunosuppressive therapy			AChEIs only	Immunosuppressive therapy			AChEIs only
	Pred	Pred + Aza	Pred + CyA		Pred	Pred + Aza	Pred + CyA	
Complete stable remission	3 [2]	–	–	–	2 [2]	–	–	4 [2]
Pharmacological remission	1 [1]	3	–	–	7 [4]	1	–	–
Minimal manifestations	1	2	–	1 [1]	1 [1]	2	–	2 [2]
Improved	8 [7]	8 [1]	5 [1]	–	4 [3]	2	1 [1]	9 [5]
Unchanged	1	1 [1]	–	1	–	3 [1]	1	2 [1]
Died of MG	–	2 [1]	–	–	–	–	–	–

Pred = prednisone; AZA = azathioprine; CyA = cyclosporin A; numbers in square brackets indicate thymectomized patients.

Table 3. Symptomatic patients had permanent weakness of cranial and bulbar muscles. Although most of these subjects were able to lead an altogether normal life and even to perform heavy work, they developed marked facial weakness and dysarthria (nasal speech) together with some atrophy of facial muscles. These findings were more common in patients with long-standing disease.

Clinical course in MuSK-negative patients

Seventeen of 41 patients received AChEI alone, 14 were treated with prednisone, eight with prednisone and azathioprine, and two with prednisone and cyclosporin A; one or more courses of P-E were performed in seven cases.

Twenty-two patients underwent thymectomy; age at surgery ranged from 15 to 62 years (mean 34 years) and 10 of 22 patients had received immunosuppressive therapy, mostly corticosteroids. The thymus was described as 'normal for age' or atrophied in most cases; however, in seven patients, a variable number of germinal centres (from very few to substantial numbers of these structures) was observed.

At the end of follow-up, six patients were in complete stable remission, eight in pharmacological remission, five showed minimal manifestations, 16 appeared improved, six were unchanged; two subjects had died of unrelated diseases. The status at the last examination in relation to treatment is reported in Table 3. No patient developed permanent weakness or muscle atrophy, and the course of the disease was, in general, less unstable than in MuSK-positive cases. However, also in this group, a few patients were affected with severe refractory symptoms in spite of long-term immunosuppressive treatment.

Case report no. 1

In May 1998, a 12-year-old girl began to complain of fluctuating ptosis and diplopia, that in the following weeks associated with dysarthria, dysphagia and facial weakness. MG was diagnosed on the basis of increased jitter on SF-EMG of orbicularis oculi muscle, while anti-AChR antibody assay was negative. Oral pyridostigmine at a dose of 30 mg, four times a day, resulted in widespread fasciculations, muscle cramps, myalgia and intestinal colic with diarrhoea;

the association of low-dose prednisone did not result in significant improvement. In the following months, the patient's symptoms worsened and she suffered from severe weight loss due to both feeding difficulties and AChEI-induced diarrhoea.

In November 2000, on admission to our hospital, the patient showed severe generalized weakness with increasing dyspnoea; after a few hours, respiratory failure ensued, requiring intubation and artificial ventilation. Treatment with high-dose prednisone and P-E resulted in marked improvement. While the patient was still on a ventilator, low-dose pyridostigmine was resumed, but had to be withdrawn as it caused prolonged contractions of abdominal muscles that interfered with mechanical ventilation.

At the last evaluation in January 2003, the patient appeared asymptomatic apart from facial weakness and mild dysarthria. Treatment consisted of 40 mg prednisone every other day and 100 mg azathioprine daily.

Case report no. 2

In May 2001, a 42-year-old woman complained of acute-onset dysphagia, dysarthria and weakness of chewing muscles; symptoms rapidly progressed to involve ocular, axial and limb muscles. MG was diagnosed on the basis of CMAP decrement on low-rate RNS; anti-AChR antibodies were negative. Treatment with oral pyridostigmine resulted in mild transient improvement, but was subsequently withdrawn on account of muscle cramps and excessive salivation.

The patient was admitted to our hospital in July 2001. The clinical picture was one of severe generalized weakness prevalent in bulbar muscles, requiring the use of a feeding tube. The patient was given P-E, associated with prednisone and azathioprine administration, with benefit. In the following months, in spite of high-dose immunosuppression (cyclosporin A replaced azathioprine because of poor tolerance), she suffered from repeated disease deterioration phases (seven in 16 months); each time she was treated with P-E with marked improvement.

At the last evaluation, in January 2003, the patient was still symptomatic with mild dysarthria, dysphagia and weakness of facial, neck and limb muscles; therapy consisted of 50 mg

prednisone on alternate days and 250 mg cyclosporin A daily. She had not required further P-E courses for the previous 4 months.

Discussion

The identification of anti-MuSK antibodies and their titration in patients' sera represents a great advance in the understanding and the diagnosing of SNMG. There was already convincing evidence that the disease was mediated by autoantibodies, such as the favourable response to immunotherapies (Soliven *et al.*, 1988; Birmanns *et al.*, 1991) and the transfer of the neuromuscular transmission defect to mice by patient's IgG injection (Mossman *et al.*, 1986; Burges *et al.*, 1994; Bufler *et al.*, 1998). However, the availability of a confirmatory test has made disease recognition easier and its treatment safer.

MuSK is a transmembrane polypeptide expressed selectively in skeletal muscle and in *Torpedo* electric organ (Valenzuela *et al.*, 1995). Its extracellular region contains four Ig-like domains and a cysteine-rich domain; its intracellular region is made of a juxtamembrane domain, a kinase domain and a C-terminal tail (Burden, 2002). MuSK is part of a receptor for agrin, a nerve-derived protein which is essential for neuromuscular synapse formation (Liyanaige *et al.*, 2002). Although agrin–MuSK interaction is not fully understood, experimental data show that agrin activation of MuSK through tyrosine phosphorylation leads to clustering of selected muscle proteins, including AChRs, and to AChR phosphorylation (Wallace *et al.*, 1991; DeChiara *et al.*, 1996). The activation of MuSK kinase requires phosphorylation of a tyrosine residue (Y553) in the juxtamembrane domain (Herbst and Burden, 2000), while the MuSK ectodomain interacts with both agrin through a hypothetical co-receptor called myotube-associated specific component (MASC) (Zhou *et al.*, 1999) and rapsyn via a putative transmembrane protein termed rapsyn-associated transmembrane ligand (RATL) (Apel *et al.*, 1997). Antibodies in patients' serum were shown to bind the ectodomain of MuSK and to reduce agrin-induced AChR clustering in culture myotubes (Hoch *et al.*, 2001).

We detected serum anti-MuSK antibodies in 47.4% of patients with SNMG. The presence of these IgGs identified a clinical picture which was remarkably similar to that reported in other MuSK-positive series (Vincent *et al.*, 2003) and corresponded to the so-called 'oculo-bulbar' form we described earlier (Evoli *et al.*, 1996). Anti-MuSK-positive MG was, in our experience, a severe disease in which vital districts such as bulbar and respiratory muscles were frequently involved. This is not, however, the only phenotype observed in these patients, as other authors (Sanders *et al.*, 2003) have recently reported in seven of 12 MuSK-positive subjects a more limited clinical picture with weakness restricted to neck extensor, shoulder and respiratory muscles. The relative frequency of these clinical variants remains to be determined. We confirm other authors' experience of a higher

prevalence of the disease in female patients (Sanders *et al.*, 2003; Vincent *et al.*, 2003). In comparison, MuSK-negative SNMG showed no sex prevalence and was characterized by a broader spectrum of age of onset and significantly milder symptoms. Differences in disease severity between these patient groups are reproduced well by the MGFA grading system, which distinguishes, in patients with mild, moderate or severe MG, the site (limb or bulbar muscles) prevalently involved (Jaretzki *et al.*, 2000).

The rare occurrence of familial cases of autoimmune MG has long been recognized (Bergoffen *et al.*, 1994). In these patients, the role of MHC, AChR and T-cell receptor genes has been investigated, with inconclusive findings (Bergoffen *et al.*, 1994; Heckmann *et al.*, 1996). We found, in single families, aggregation of both MuSK-positive and MuSK-negative SNMG with AChR-positive MG. Thus, distinct diseases, caused by different pathogenic antibodies, were present in the affected members of the same family. This association did not appear to be linked to MHC genes, at least in the family studied so far (Evoli *et al.*, 1995).

The diagnosis of SNMG, especially in MuSK-positive patients, may present difficulties due to false-negative results from EMG studies. SF-EMG proved to be, also in our experience, the most sensitive examination in the electrophysiological diagnosis of the disease (Oh, 1993) while, owing to weakness topography, RNS in limb muscles was positive in <60% of cases. Another potentially confounding factor can be represented by the response to AChEI. Almost 30% of MuSK-positive patients showed equivocal or negative reactions to edrophonium or neostigmine injection, and the chronic administration of pyridostigmine was even more unsatisfactory, causing more side effects than weakness relief. As a consequence, we think that a negative response to AChEI should by no means rule out the diagnosis of MG in these cases. Our patients underwent extensive EMG studies and even muscle biopsy in order to exclude disorders other than MG. Anti-MuSK antibody assay, which in our and others' experience has proved to be highly specific (Vincent *et al.*, 2003), will help to overcome these diagnostic difficulties. The diagnosis of MG was comparatively easier in MuSK-negative patients, in whom the diagnostic yield of both EMG and pharmacological tests was similar to that observed in SPMG cases.

The role of thymectomy in MuSK-positive MG is very uncertain. Inasmuch as most patients in our series were thymectomized in their teens or early twenties, thymus hyperplastic changes were absent, thus arguing against a role for the thymus in the pathogenesis of the disease. In agreement with other authors (Sanders *et al.*, 2003), we did not observe any clear benefit from surgery as most of these subjects were receiving immunosuppression and remained dependent upon it.

The great majority of MuSK-positive patients required immunosuppressive treatment. At the end of the observation period, although two subjects had died of their disease, a few had acquired remission and most symptomatic patients had a

substantially stable disease. Thus, these patients appear to respond to corticosteroids, cyclosporin A and, in our experience, also to azathioprine, while others (Sanders *et al.*, 2003) have reported no benefit from this drug. The overall response to immunosuppressive therapy, however, can be considered less satisfactory than that in SPMG patients on the basis of two observations: first, high-dose treatment did not prevent frequent disease deteriorations, requiring emergency treatment; secondly, many patients developed over the years, permanent cranial and bulbar symptoms, especially facial weakness and nasal speech. Such a picture, which can also be seen in long-standing SPMG, is a rare finding at present (Oosterhuis, 1984), owing to the early use of immunosuppressive therapy. It remains to be determined whether alternative treatments such as mycophenolate mofetyl or high-dose cyclophosphamide that have been used successfully in treating these patients (Drachman *et al.*, 2003; Sanders *et al.*, 2003) would have been more effective or whether such changes are the specific result of the autoimmune attack on MuSK in subjects with long-standing disease.

In comparison, MuSK-negative MG appears to be a more heterogeneous disease. In most cases, it was clinically indistinguishable from SPMG and responded well to treatment. However, also in this group, there were patients with refractory disease, poorly responsive to both AChEIs and immunosuppressants. It would be interesting to determine whether in some of these subjects serum factors distinct from MuSK are at work as pathogenic agents.

References

- Apel ED, Glass DJ, Moscoso LM, Yancopoulos GD, Sanes JR. Rapsyn is required for MuSK signaling and recruits synaptic components to a MuSK-containing scaffold. *Neuron* 1997; 18: 623–35.
- Bartoccioni E, Scuderi F, Scoppetta C, Evoli A, Tonali P, Guidi L, et al. Myasthenia gravis, thymectomy, and antiacetylcholine receptor antibody. *J Neurol* 1980; 224: 9–15.
- Bergoffen J, Zmijewski CM, Fischbeck KH. Familial autoimmune myasthenia gravis. *Neurology* 1994; 44: 551–4.
- Birmanns B, Brenner T, Abramsky O, Steiner I. Seronegative myasthenia gravis: clinical features, response to therapy and synthesis of acetylcholine receptor antibodies in vitro. *J Neurol Sci* 1991; 102: 184–9.
- Buffer J, Pitz R, Czep M, Wick M, Franke C. Purified IgG from seropositive and seronegative patients with myasthenia gravis reversibly blocks currents through nicotinic acetylcholine receptor channels. *Ann Neurol* 1998; 43: 458–64.
- Burden SJ. Building the vertebrate neuromuscular synapse. [Review]. *J Neurobiol* 2002; 53: 501–11.
- Burges J, Vincent A, Molenaar PC, Newsom-Davis J, Peers C, Wray D. Passive transfer of seronegative myasthenia gravis to mice. *Muscle Nerve* 1994; 17: 1393–400.
- DeChiara TM, Bowen DC, Valenzuela DM, Simmons MV, Poueymirou WT, Thomas S, et al. The receptor tyrosine kinase MuSK is required for neuromuscular junction formation in vivo. *Cell* 1996; 85: 501–12.
- Drachman DB, Jones RJ, Brodsky RA. Treatment of refractory myasthenia: ‘Rebooting’ with high-dose cyclophosphamide. *Ann Neurol* 2003; 53: 29–34.
- Evoli A, Batocchi AP, Zelano G, Uncini A, Palmisani MT, Tonali P. Familial autoimmune myasthenia gravis: report of four families. *J Neurol Neurosurg Psychiatry* 1995; 58: 729–31.
- Evoli A, Batocchi AP, Lo Monaco M, Servidei S, Padua L, Majolini L, et al. Clinical heterogeneity of seronegative myasthenia gravis. *Neuromuscul Disord* 1996; 6: 155–61.
- Heckmann JM, Morrison KE, Emerik-Szajewska B, Strugalska H, Bergoffen B, Willcox N, et al. Human muscle acetylcholine receptor alpha-subunit gene (CHRNA1) association with autoimmune myasthenia gravis in black, mixed-ancestry and Caucasian subjects. *J Autoimmun* 1996; 9: 175–80.
- Herbst R, Burden SJ. The juxtamembrane region of MuSK has a critical role in agrin mediated signaling. *EMBO J* 2000; 19: 67–77.
- Hoch W, McConville J, Helms S, Newsom-Davis J, Melms A, Vincent A. Auto-antibodies to the receptor tyrosine kinase MuSK in patients with myasthenia gravis without acetylcholine receptor antibodies. *Nat Med* 2001; 7: 365–8.
- Jaretzki A 3rd, Barohn RJ, Ernstoff RM, Kaminski HJ, Keeseey JC, Penn AS, et al. Myasthenia gravis: recommendations for clinical research standards. Task force of the Medical Scientific Advisory Board of the Myasthenia Gravis Foundation of America. [Review]. *Neurology* 2000; 55: 16–23.
- Keeseey J. A treatment algorithm for autoimmune myasthenia in adults. *Ann NY Acad Sci* 1998; 841: 753–68.
- Lindstrom J. An assay for antibody to human acetylcholine receptor in serum from patients with myasthenia gravis. *Clin Immunol Immunopathol* 1977; 7: 36–43.
- Liyanage Y, Hoch W, Beeson D, Vincent A. The agrin/muscle-specific kinase pathway: new targets for autoimmune and genetic disorders at the neuromuscular junction. [Review]. *Muscle Nerve* 2002; 25: 4–16.
- Mossman S, Vincent A, Newsom-Davis J. Myasthenia gravis without acetylcholine receptor antibody: a distinct disease entity. *Lancet* 1986; 1: 116–9.
- Oh SJ. Electrophysiological characteristics in seronegative myasthenia gravis. *Ann NY Acad Sci* 1993; 681: 584–7.
- Oosterhuis HJGH Myasthenia gravis. In: *Clinical neurology and neurosurgery monographs*. Edinburgh: Churchill Livingstone; 1984. p. 21–50.
- Plested CP, Tang T, Spreadbury I, Littleton ET, Kishore U, Vincent A. AChR phosphorylation and indirect inhibition of AChR function in seronegative myasthenia gravis. *Neurology* 2002; 59: 1682–8.
- Sanders DB, El-Salem K, Massey JM, McConville J, Vincent A. Clinical aspects of MuSK antibody positive seronegative MG. *Neurology*. In press 2003.
- Schuberth HJ, Kroell A, Leibold W. Biotinylation of cell surface

MHC molecules: a complementary tool for the study of MHC class II polymorphism in cattle. *J Immunol Methods* 1996; 189: 89–98.

Scuderi F, Marino M, Colonna L, Mannella F, Evoli A, Provenzano C, et al. Anti-p110 autoantibodies identify a subtype of 'seronegative' myasthenia gravis with prominent oculobulbar involvement. *Lab Invest* 2002; 82: 1139–46.

Soliven BC, Lange DJ, Penn AS, Younger D, Jaretzki A 3rd, Lovelace RE, et al. Seronegative myasthenia gravis. *Neurology* 1988; 38: 514–7.

Valenzuela DM, Stitt TN, DiStefano PS, Rojas E, Mattsson K, Compton DL, et al. Receptor tyrosine kinase specific for the skeletal muscle lineage: expression in embryonic muscle, at the neuromuscular junction, and after injury. *Neuron* 1995; 15: 573–84.

Verma PK, Oger JJ. Seronegative generalized myasthenia gravis: low frequency of thymic pathology. *Neurology* 1992; 42: 586–9.

Vincent A, Li Z, Hart A, Barrett-Jolley R, Yamamoto T, Burges J, et al. Seronegative myasthenia gravis. Evidence for plasma factor(s) interfering with acetylcholine receptor function. *Ann NY Acad Sci* 1993; 681: 529–38.

Vincent A, Bowen J, Newsom-Davis J, McConville J. Seronegative generalised myasthenia gravis: clinical features, antibodies, and their targets. [Review]. *Lancet Neurol* 2003; 2: 99–106.

Wallace BG, Qu Z, Haganir RL. Agrin induces phosphorylation of the nicotinic acetylcholine receptor. *Neuron* 1991; 6: 869–78.

Zhou H, Glass DJ, Yancopoulos GD, Sanes JR. Distinct domains of MuSK mediate its abilities to induce and to associate with postsynaptic specializations. *J Cell Biol* 1999; 146: 1133–46.

Received March 26, 2003.

Revised May 6, 2003. Accepted May 10, 2003